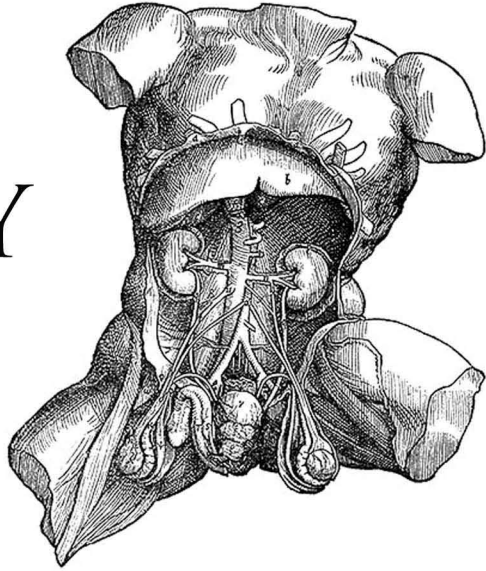


ANATOMY OF THE HUMAN BODY

PART 3

HENRY GRAY



- 01 - Angiology: Introduction
- 02 - The Blood
- 03 - Development of the Vascular System, Part 1
- 04 - Development of the Vascular System, Part 2
- 05 - The Thoracic Cavity; The Pericardium
- 06 - The Heart, Part 1
- 07 - The Heart, Part 2
- 08 - Peculiarities in the Vascular System in the Fetus
- 09 - The Arteries: Introduction
- 10 - The Aorta
- 11 - The Common Carotid Artery
- 12 - The External Carotid Artery, Part 1
- 13 - The External Carotid Artery, Part 2
- 14 - The Triangles of the Neck
- 15 - The Internal Carotid Artery
- 16 - The Arteries of the Brain
- 17 - Arteries of the Upper Extremity: The Subclavian Artery, Part 1
- 18 - The Subclavian Artery, Part 2
- 19 - The Axilla; The Axillary Artery
- 20 - The Brachial Artery
- 21 - The Radial Artery
- 22 - The Ulnar Artery
- 23 - Arteries of the Trunk: Descending Aorta; Thoracic Aorta
- 24 - The Abdominal Aorta, Part 1
- 25 - The Abdominal Aorta, Part 2
- 26 - The Common Iliac Arteries
- 27 - The Hypogastric Artery
- 28 - The External Iliac Artery
- 29 - The Arteries of the Lower Extremity: The Femoral Artery
- 30 - The Popliteal Fossa; The Popliteal Artery
- 31 - Anterior Tibial Artery; Arteria Dorsalis Pedis
- 32 - The Posterior Tibial Artery
- 33 - The Veins: Introduction
- 34 - Pulmonary Veins; Systemic Veins: Veins of the Heart
- 35 - Veins of Head and Neck: Veins of Exterior of Head and Face
- 36 - Veins of the Neck
- 37 - The Diploic Veins; Veins of the Brain
- 38 - Sinuses of Dura Mater, Ophthalmic Veins, Emissary Veins
- 39 - Veins of Upper Extremity and Thorax
- 40 - Veins of Lower Extremity, Abdomen, and Pelvis, Part 1
- 41 - Veins of Lower Extremity, Abdomen, and Pelvis, Part 2
- 42 - The Portal System of Veins
- 43 - The Lymphatic System: Introduction
- 44 - The Thoracic Duct
- 45 - Lymphatics of the Head, Face, and Neck
- 46 - Lymphatics of the Upper Extremity
- 47 - Lymphatics of the Lower Extremity
- 48 - Lymphatics of the Abdomen and Pelvis, Part 1
- 49 - Lymphatics of the Abdomen and Pelvis, Part 2
- 50 - Lymphatic Vessels of the Thorax

Read by: Laurie Anne Walden, Julie VW, Lee Ann Howlett, Suzisinger, MorganScorpion, J.M. Smallheer, Jennifer Stearns, Celena Arter, Elli, EHehl, Neeru Iyer, Annise, Bellona Times, Rachel Gatwood, Marianne Coleman-Hipkins, David Lawrence, Carolyn Power